

CASE REPORT

A case of classic Kaposi's sarcoma masquerading as a vascular malformation

Howroyd LR,¹ Milroy C,² Ray S,³ Morgan R,¹ Ratnam LA¹

1. Department of Radiology, St George's University Hospital NHS Foundation Trust, London, UK
2. Department of Plastic Surgery, St George's University Hospital NHS Foundation Trust, London, UK
3. Department of Vascular Surgery, Kingston Hospital NHS Foundation Trust, Galsworthy Road, Kingston upon Thames, UK

Corresponding author:
Lucy-Rose Howroyd
Department of Radiology,
St George's University Hospital
NHS Foundation Trust,
London SW17 0QT, UK
Email: rose.howroyd@stgeorges.nhs.uk

Received: 29th January 2024
Accepted: 15th April 2024
Online: 1st May 2024

Key words: Kaposi's sarcoma, arteriovenous malformation, Bluefarb syndrome

Abstract

A 45-year-old man presented with painful lumps on his right foot. Imaging suggested a vascular malformation and the patient was referred first to a vascular surgeon, then to a specialist vascular malformation centre. MRA and catheter angiography confirmed a high flow lesion. However, there was clinical and radiological suspicion that an alternative diagnosis was possible. Biopsy confirmed the lesions to be Kaposi's sarcoma. Arteriovenous malformations and Kaposi's sarcoma can appear almost identical clinically and radiologically, so histological analysis is important if there are any doubts about the diagnosis.

Case report

A 45-year-old man presented with a painful lump on his right foot, which had been slowly increasing in size over approximately 9 months and was interfering with his daily activities. He was a

marathon runner and had stopped running due to the pain. There was no past medical or family history of note and he had never smoked. He was born in Tunisia and emigrated to the UK.

An ultrasound requested by the primary care doctor described an arteriovenous malformation (AVM) and he was referred to a vascular surgeon at a district general hospital, who found a lobulated subcutaneous mass including soft and fibrotic areas and attributed the pain to repeated thrombosis (Figure 1). He was recommended daily aspirin, an MRA of his foot was requested and he was referred to a specialised unit dealing in vascular malformations for consideration of sclerotherapy.

The MRA (Figure 2) showed distinct but communicating lesions with arterial supply and early venous drainage, suggestive of an arteriovenous lesion. A specialist multidisciplinary team (MDT), consisting of dermatology, vascular, diagnostic and interventional radiology experts, considered the lesions too high flow (ie, arterial) for sclerotherapy and recommended a diagnostic angiogram with a view to possible endovascular embolisation.

Figure 1 Photograph of right foot showing painful growing lumps on the medial aspect of the foot.

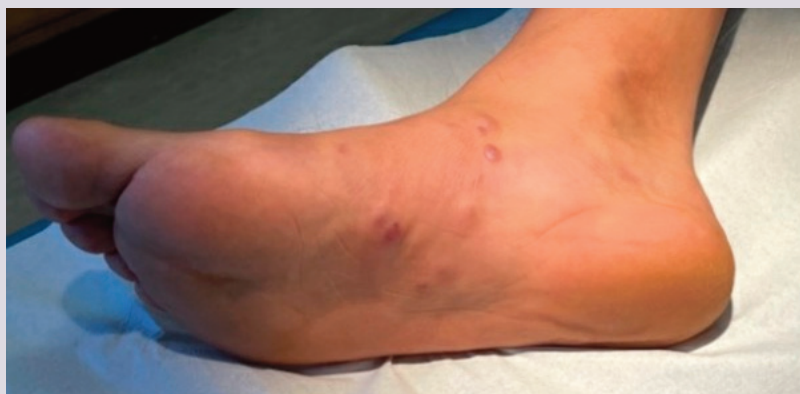
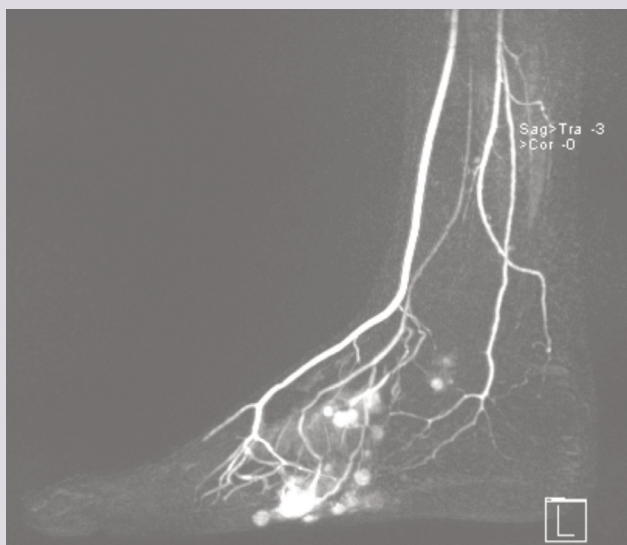
Figure 2 MRA of right foot. Lateral ankle view showing several lesions with arterial supply and early venous drainage.



The diagnostic angiogram (Figure 3) showed abnormal feeding arteries and early venous pooling. Embolisation was not felt to be appropriate due to the high risk of resultant tissue loss and the case was rediscussed in the specialist MDT. Concerns were raised regarding the diagnosis as the lesions had multiplied and were felt to be disproportionately painful since the initial presentation. The decision was made to perform a biopsy prior to any further treatment. Microscopy showed spindle cells with mild atypia, scattered lymphocytes and extravasation of red blood cells. Staining with human herpes virus 8 (HHV8) was strongly positive. The biopsy was diagnostic of Kaposi's sarcoma.

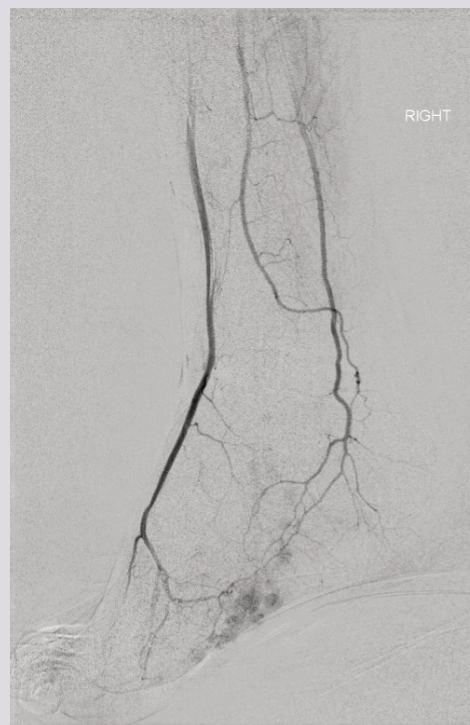
The patient was seen in an oncology clinic, now with multiple lumps on his foot and one on his shin. A viral panel showed he was HHV8 positive and HIV negative. A CT scan of his thorax, abdomen and pelvis showed no concerning lymph nodes or visceral lesions. Radiotherapy was not considered to be appropriate due to the number of lesions and the patient was commenced on a course of chemotherapy (pegylated liposomal doxorubicin). The patient completed eight cycles of chemotherapy but, unfortunately, he presented again 6 months later with new lesions in his foot for which he is currently being restaged.

Discussion

Vascular malformations encompass a wide spectrum of lesions. A fundamental radiological classification is whether the lesion is high or low flow,¹ which can be further expanded based on flow dynamics and cellular features.²

AVMs are vascular malformations resulting from developmental defects of the arterial and venous vasculature. They affect any organ, most commonly the head and neck (specifically the most frequent are intracranial AVMs) followed by the extremities. The

Figure 3 Right lower limb angiogram. Lateral ankle view showing several arteriovenous connections in the right foot arising from the plantar arch with rapid venous drainage.



exact aetiology is unclear. To our knowledge, there are no published data regarding the incidence of peripheral AVMs. The incidence of intracranial AVMs is around 1–10/100,000.^{3–5}

Although AVMs are thought to be present at birth, if they are deep or slow growing the patient may not present until adulthood. AVMs can be solitary or multifocal, and usually are slow growing but can grow rapidly. They often present with pain and swelling and can be red/blue/purple in colour.

Kaposi's sarcoma is a low-grade vasoformative/angioproliferative neoplasm (sarcoma is a misnomer) associated with HHV8, also known as Kaposi's sarcoma-associated herpes virus (KSHV).^{6–8} There are four main subtypes of Kaposi's sarcoma: classic, endemic (observed in sub-Saharan Africa), epidemic (AIDS related), and iatrogenic (transplant related).

Classic Kaposi's sarcoma is what was originally described by Kaposi in 1872,⁹ a cutaneous tumour affecting primarily the skin over the lower legs and feet in a multifocal and classically symmetrical distribution. Kaposi's sarcoma often occurs in older males of Mediterranean (such as Tunisian) or Central/Eastern European ancestry. It is likely multifactorial with one factor being that HHV8 infection rates are substantially higher in these parts of the world.^{10–12} Additionally, it is thought that people with classic Kaposi's sarcoma are born with a genetic/immunological vulnerability to the HHV8 virus.^{6,7,13,14} Transmission routes of HHV8 are not fully understood, but both vertical and horizontal

transmission are established and it is thought to be via bodily fluids including saliva.^{8,15}

The incidence rate of classic Kaposi's sarcoma in the UK is thought to be around 0.014/100,000 person-years.¹⁶ However, in Sardinia the incidence rate was estimated at 1.58/100000 person-years.¹⁷

Classic Kaposi's sarcoma is characterised by the appearance of purplish, reddish blue or dark brown/black macules, plaques and nodules on the skin. The lesions vary from very small to several centimetres in diameter. They can remain unchanged for months to years or may grow rapidly and can be accompanied by contemporaneous mucous membrane and visceral lesions.

It is well established that the cutaneous manifestation of Kaposi's sarcoma and an AVM can be similar.^{18–22} Most cases reported in the literature are of 'pseudo-Kaposi's sarcoma', also eponymously called Stewart–Bluefarb syndrome, where the patient is initially thought to have classic Kaposi's sarcoma and it is discovered to be an AVM. Indeed, to our knowledge there is only one case report describing a case of Kaposi's sarcoma which was initially thought to represent an AVM.²¹ It is unusual for these cases to be presented in vascular journals and therefore vascular clinicians may not be aware of this diagnostic pitfall.

This case report serves to highlight to those involved in the patient's journey that these two conditions can be almost indistinguishable both clinically and radiologically. If there is any uncertainty in the history, examination or imaging, then a biopsy and histopathological analysis should be obtained prior to any definitive treatment. The treatment of the two conditions is very different and diagnostic delay can have detrimental consequences for the patient.

Conflict of Interest: None.

Funding: None.

Patient consent to publication: Informed consent was obtained from the patient for this publication.

Reviewer acknowledgement: *JVSGBI* thanks the Editorial team for their contribution to the peer review of this work.

References

- Jackson IT, Carreño R, Potparic Z, Hussain K. Hemangiomas, vascular malformations, and lymphovenous malformations. *Plast Reconstr Surg* 1993; **91**(7):1216–30. <https://doi.org/10.1097/00006534-199306000-00006>
- Kunimoto K, Yamamoto Y, Jinnin M. ISSVA classification of vascular anomalies and molecular biology. *Int J Mol Sci* 2022; **23**(4):2358. <https://doi.org/10.3390/ijms23042358>
- Eifert S, Villavicencio JL, Kao TC, Taute BM, Rich NM. Prevalence of deep venous anomalies in congenital vascular malformations of venous predominance. *J Vasc Surg* 2000; **31**(3):462–71.
- Jacobs AH, Walton RG. The incidence of birthmarks in the neonate. *Pediatrics* 1976; **58**(2):218–22.
- Gautam A, Sun Z, Winkler E, *et al*. Concurrent presentation of brain arteriovenous malformation, peripheral arteriovenous malformation, and cerebellar astrocytoma: case report. *Interdiscip Neurosurg* 2020; **20**:100689. <https://doi.org/10.1016/j.inat.2020.100689>
- Gao SJ, Kingsley L, Hoover DR, *et al*. Seroconversion to antibodies against Kaposi's sarcoma-associated herpesvirus-related latent nuclear antigens

KEY MESSAGES

- Kaposi's sarcoma occurs in patients other than immunosuppressed/HIV positive patients.
- Arteriovenous malformations and classic Kaposi's sarcoma can be clinically and radiologically indistinguishable.
- Biopsy and histopathological assessment are crucial to differentiating between the two if there is any diagnostic uncertainty.

- before the development of Kaposi's sarcoma. *N Engl J Med* 1996; **335**(4): 233–41. <https://doi.org/10.1056/NEJM199607253350403>
- Gao SJ, Kingsley L, Li M, *et al*. KSHV antibodies among Americans, Italians and Ugandans with and without Kaposi's sarcoma. *Nat Med* 1996; **2**(8):925–8. <https://doi.org/10.1038/nm0896-925>
 - Martin JN, Ganem DE, Osmond DH, Page-Shafer KA, Macrae D, Kedes DH. Sexual transmission and the natural history of human herpesvirus 8 infection. *N Engl J Med* 1998; **338**(14):948–54. <https://doi.org/10.1056/NEJM199804023381403>
 - Kaposi M. Idiopathisches multiples Pigmentsarkom der Haut. *Arch Dermatol Syph* 1872; **4**(2):265–73.
 - Cattani P, Cerimele F, Porta D, *et al*. Age-specific seroprevalence of human herpesvirus 8 in Mediterranean regions. *Clin Microbiol Infect* 2003; **9**(4):274–9. <https://doi.org/10.1046/j.1469-0691.2003.00490.x>
 - Angeloni A, Heston L, Uccini S, *et al*. High prevalence of antibodies to human herpesvirus 8 in relatives of patients with classic Kaposi's sarcoma from Sardinia. *J Infect Dis* 1998; **177**(6):1715–8. <https://doi.org/10.1086/517429>
 - Iscovich J, Boffetta P, Winkelmann R, Brennan P, Azizi E. Classic Kaposi's sarcoma in Jews living in Israel, 1961–1989: a population-based incidence study. *AIDS* 1998; **12**(15):2067–72. <https://doi.org/10.1097/00002030-199815000-00019>
 - Brown EE, Fallin MD, Goedert JJ, *et al*. A common genetic variant in FCGR3A-V158F and risk of Kaposi sarcoma herpesvirus infection and classic Kaposi sarcoma. *Cancer Epidemiol Biomarkers Prev* 2005; **14**(3):633–7. <https://doi.org/10.1158/1055-9965.EPI-04-0598>
 - Anderson LA, Lauria C, Romano N, *et al*. Risk factors for classical Kaposi sarcoma in a population-based case-control study in Sicily. *Cancer Epidemiol Biomarkers Prev* 2008; **17**(12):3435–43. <https://doi.org/10.1158/1055-9965.EPI-08-0671>
 - Pauk J, Huang ML, Brodie SJ, *et al*. Mucosal shedding of human herpesvirus 8 in men. *N Engl J Med* 2000; **343**(19):1369–77. <https://doi.org/10.1056/NEJM200011093431904>
 - Gulich A, Beral V, Swerdlow A. Kaposi's sarcoma in England and Wales before the AIDS epidemic. *Br J Cancer* 1992; **66**(6):1135–7. <https://doi.org/10.1038/bjc.1992.423>
 - Cottoni F, De Marco R, Montesu M. Classical Kaposi's sarcoma in north-east Sardinia: an overview from 1977 to 1991. *Br J Cancer* 1996; **73**(9):1132–3. <https://doi.org/10.1038/bjc.1996.217>
 - Marshall ME, Hatfield ST, Hatfield DR. Arteriovenous malformation simulating Kaposi's sarcoma (pseudo-Kaposi's sarcoma). *Arch Dermatol* 1985; **121**(1): 99–101.
 - Earhart RN. Pseudo-Kaposi sarcoma. A patient with arteriovenous malformation and skin lesions simulating Kaposi sarcoma. *Arch Dermatol* 1974; **110**(6):907–10. <https://doi.org/10.1001/archderm.110.6.907>
 - Bluefarb SM, Adams LA. Arteriovenous malformation with angiodermatitis. Stasis dermatitis simulating Kaposi's disease. *Arch Dermatol* 1967; **96**(2): 176–81.
 - Witt JD, Jupiter JB. Kaposi's sarcoma in the hand seen as an arteriovenous malformation. *J Hand Surg Am* 1991; **16**(4):607–9. [https://doi.org/10.1016/0363-5023\(91\)90182-b](https://doi.org/10.1016/0363-5023(91)90182-b)
 - Larralde M, Gonzalez V, Marietti R, Nussebaum D, Peirano M, Schroh R. Pseudo Kaposi sarcoma with arteriovenous malformation. *Pediatr Dermatol* 2001; **18**(4):325–7. <https://doi.org/10.1046/j.1525-1470.2001.01934.x>